



Functional Hoof Care

Healthy Hooves India

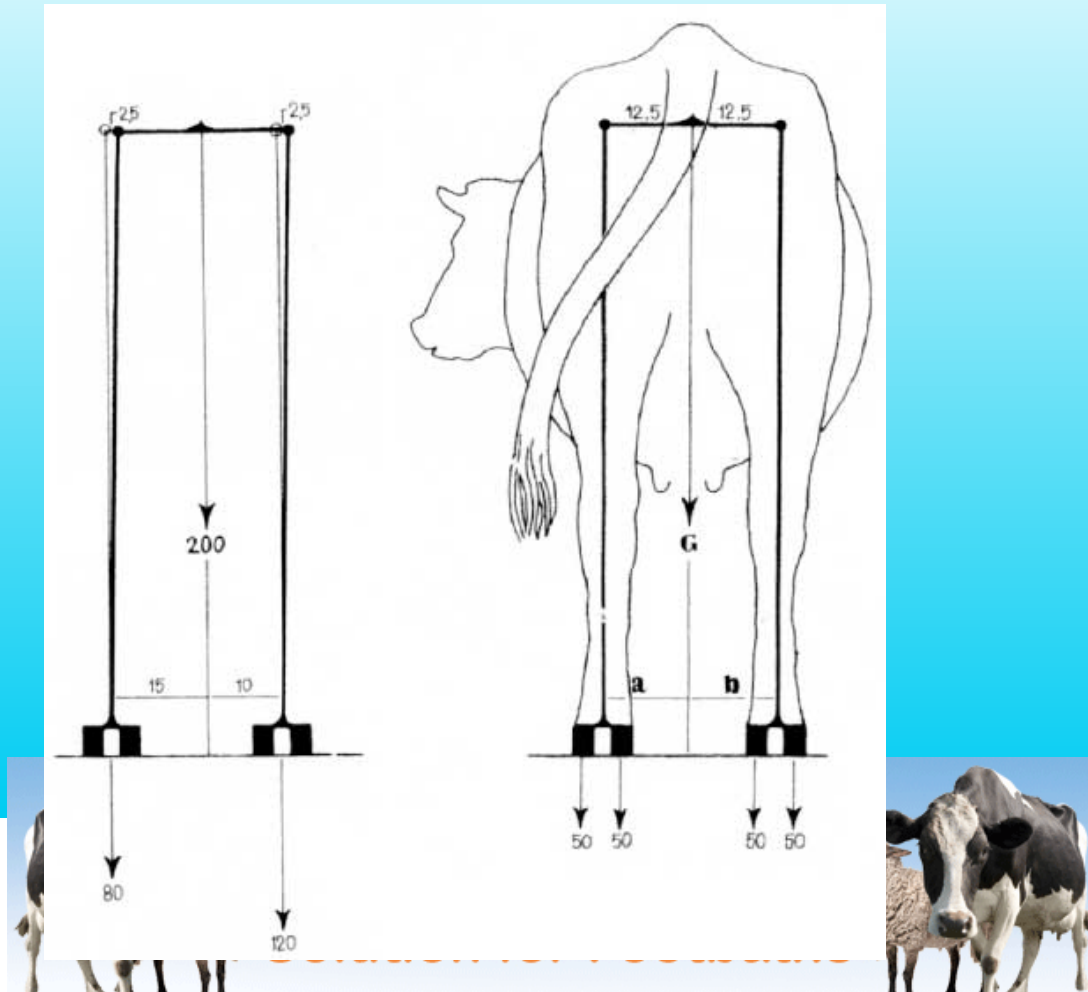
Westpoint Farm Vets



westpoint veterinary group



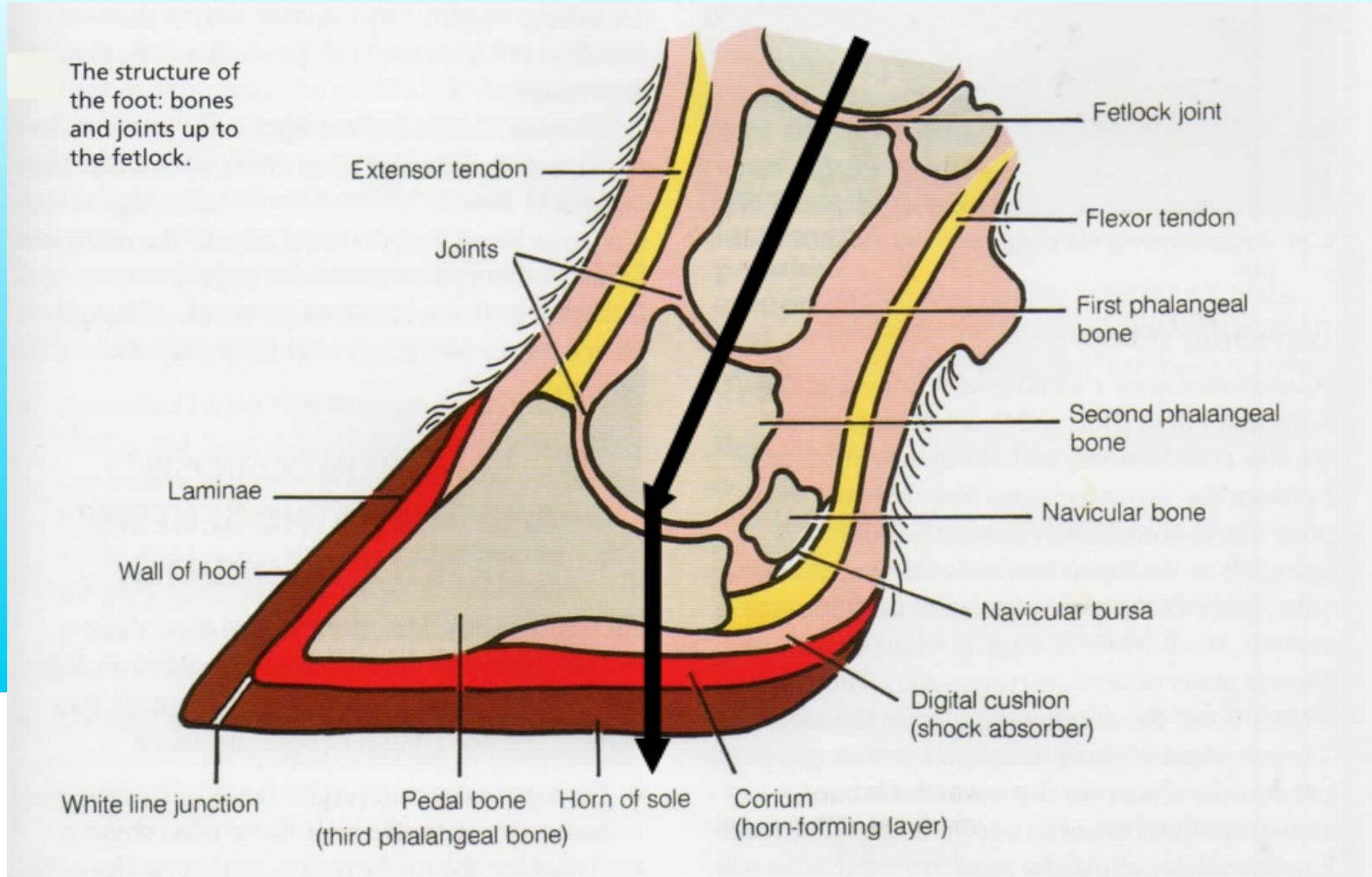
Functional Hoof Anatomy



westpoint veterinary group

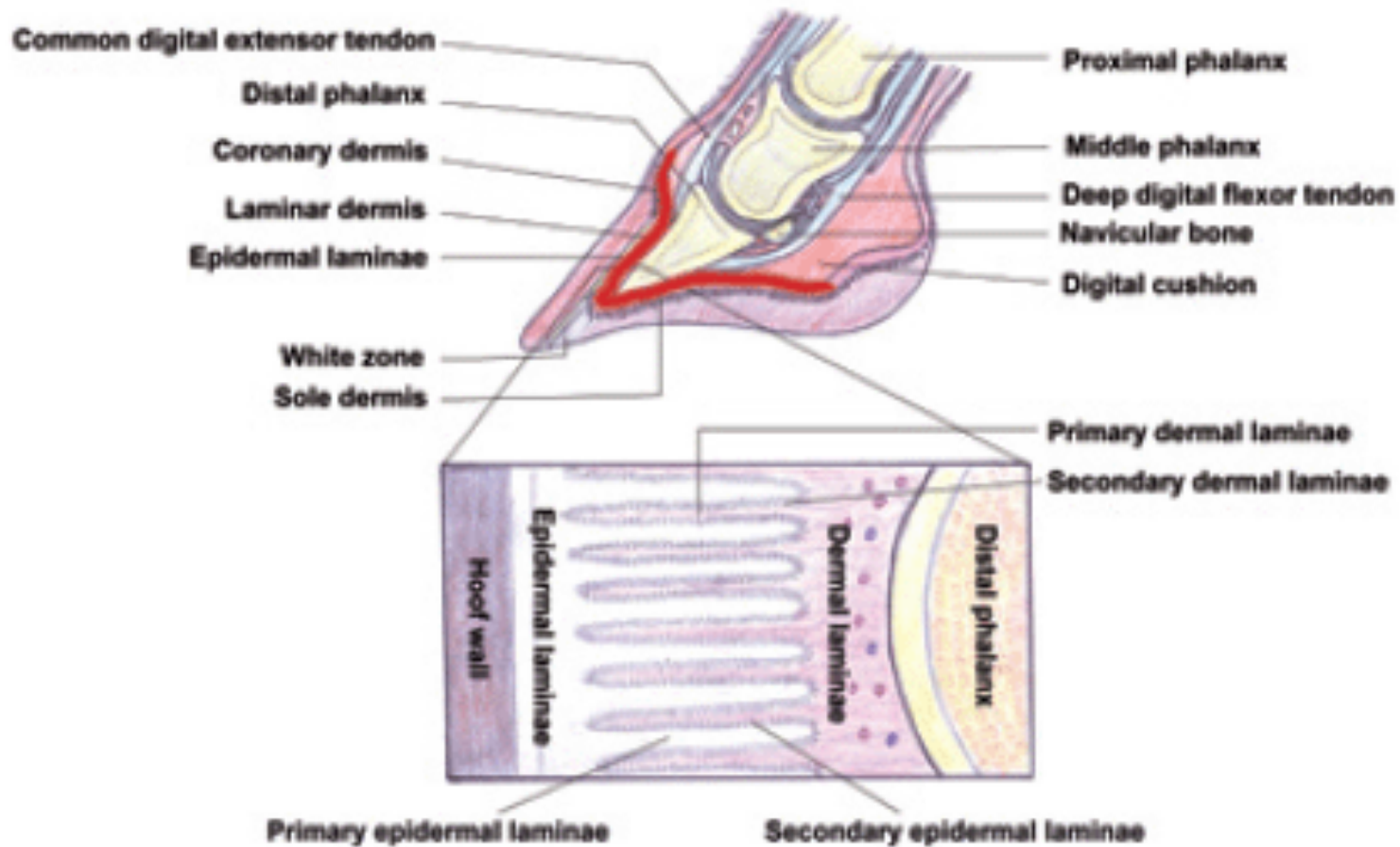


Functional Hoof Anatomy



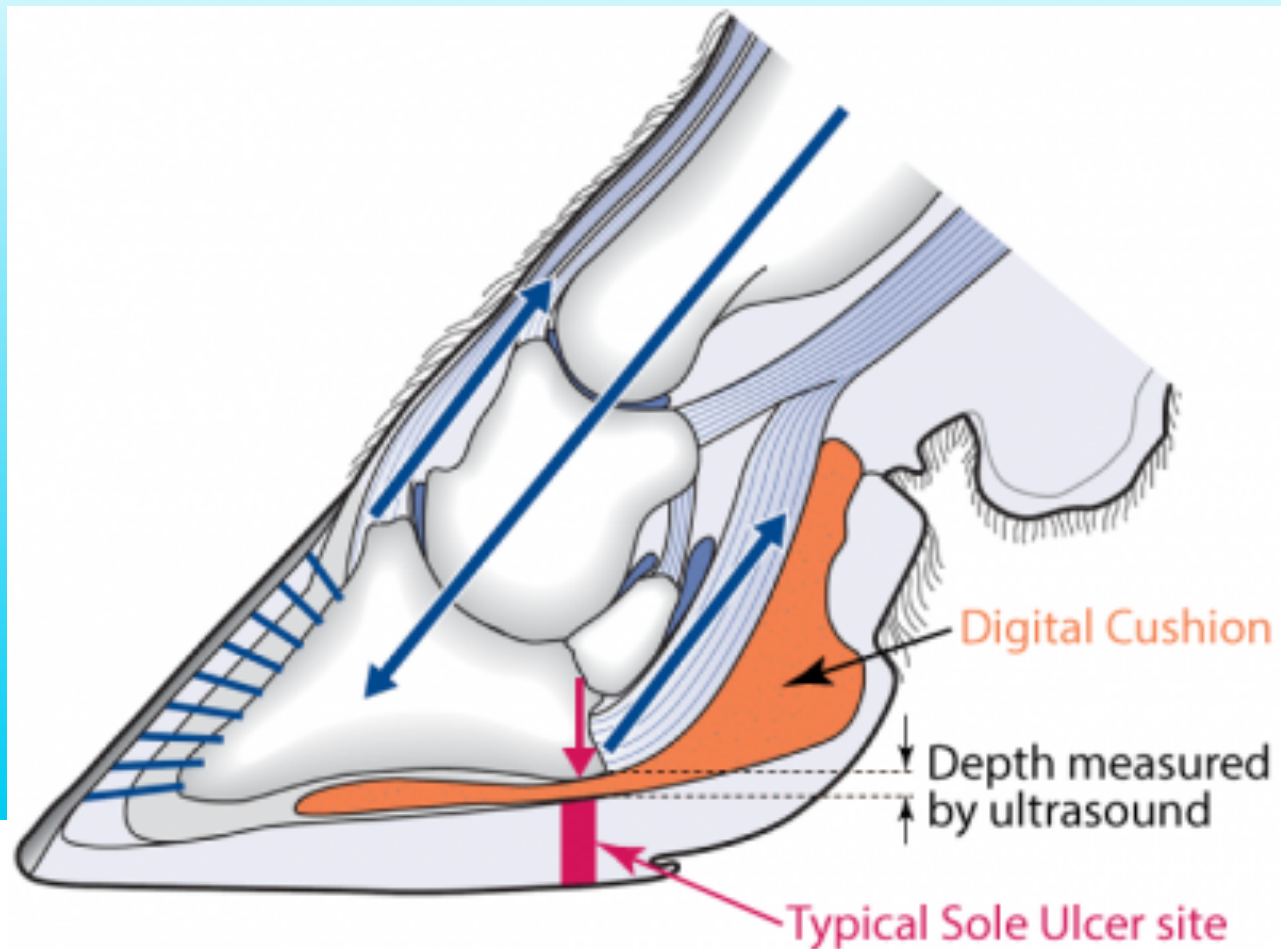


Functional Hoof Anatomy





Functional Hoof Anatomy





Routine Hoofcare



westpoint veterinary group



Causes of lameness

Interdigital necrobacillosis, foul-in-the-foot, footrot, interdigital pododermatitis, superfoul, solar ulcer, toe ulcer, wall ulcer, under-run sole, subsolar haemorrhage, subsolar bruising, digital dermatitis, Mortellaro's disease, corn, interdigital granuloma, fibroma, hairy wart, interdigital papillodermatitis, strawberry footrot, Rusterholz ulcer, toe necrosis, septic pedal arthritis, white line disease, etc, etc, etc



westpoint veterinary group



Causes of lameness

Diseases of the horn

Diseases of the skin

Secondary conditions



westpoint veterinary group

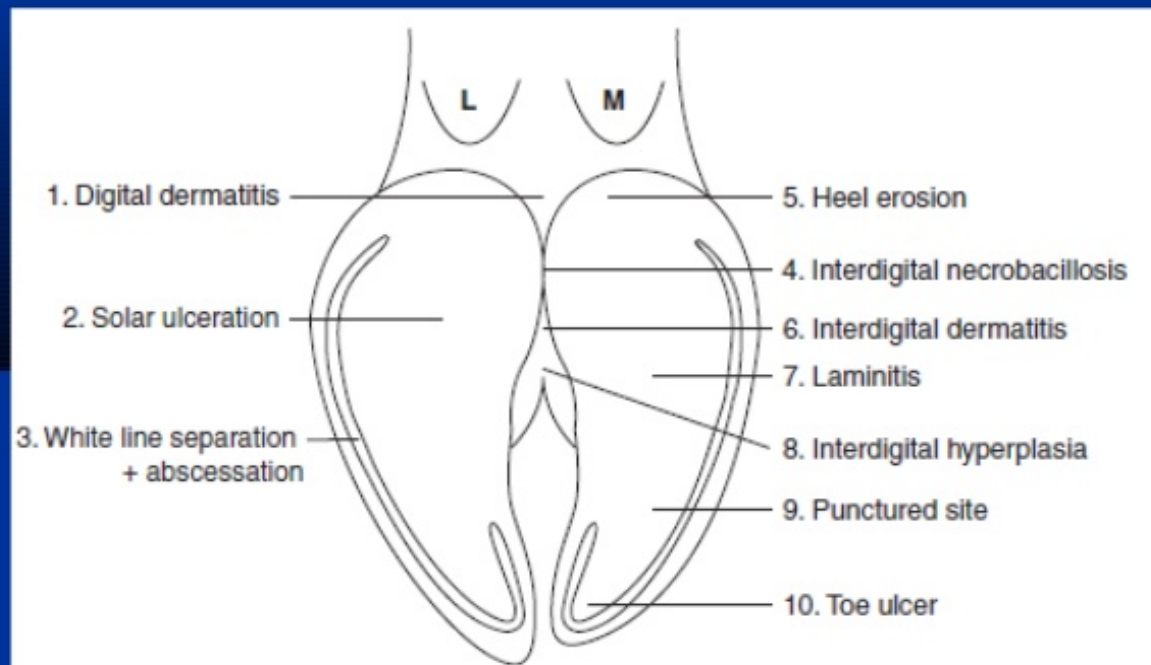


Figure 7.2 Important conditions of the bovine digit.

1. digital dermatitis; 2. sole ulceration; 3. white line separation and abscessation; 4. interdigital necrobacillosis; 5. heel erosion; 6. interdigital dermatitis; 7. laminitis/sole haemorrhage; 8. interdigital hyperplasia; 9. punctured sole; 10. toe ulcer.



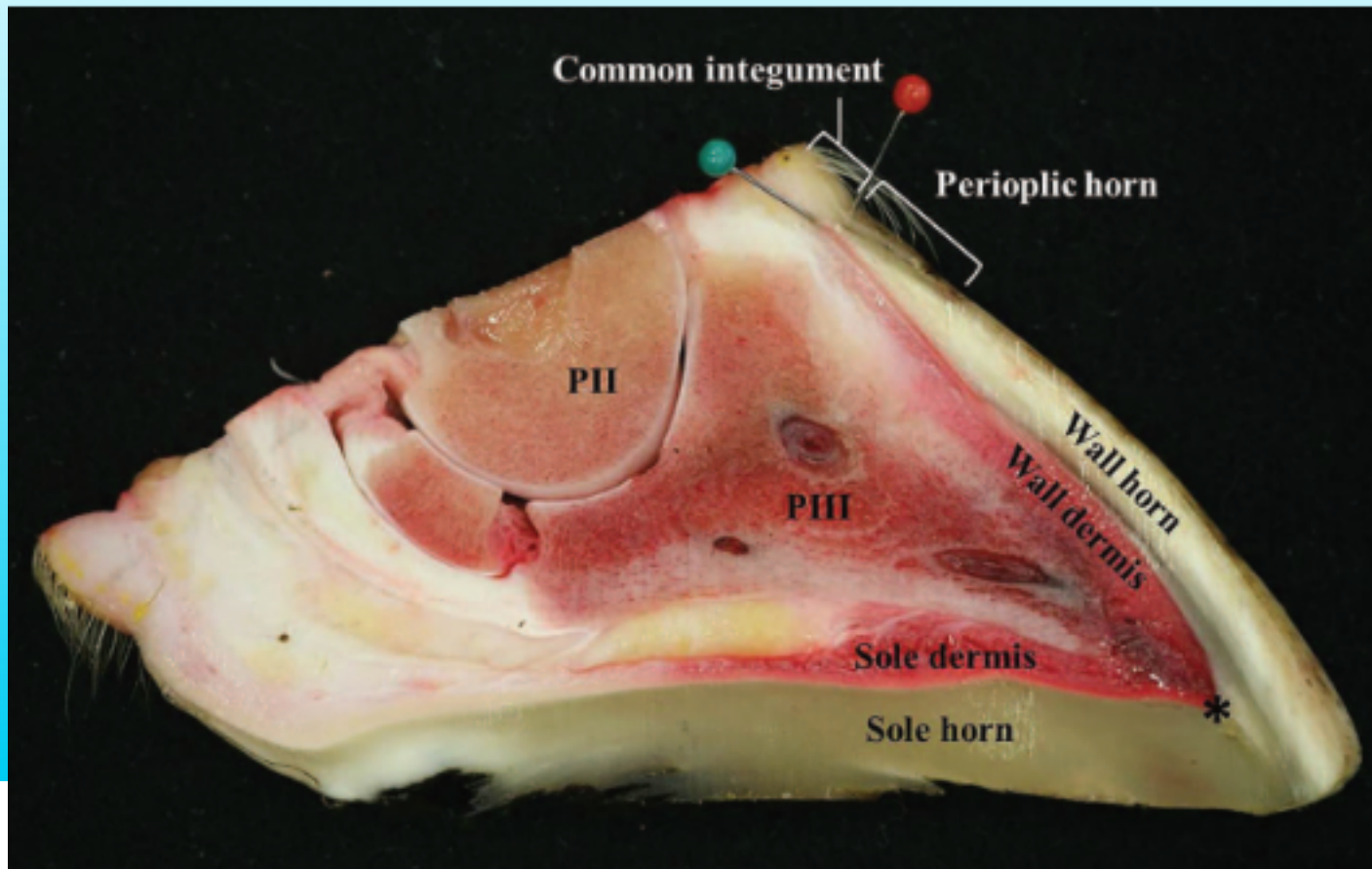
Healthy Hooves[®]
Solution for Footbaths



westpoint veterinary group

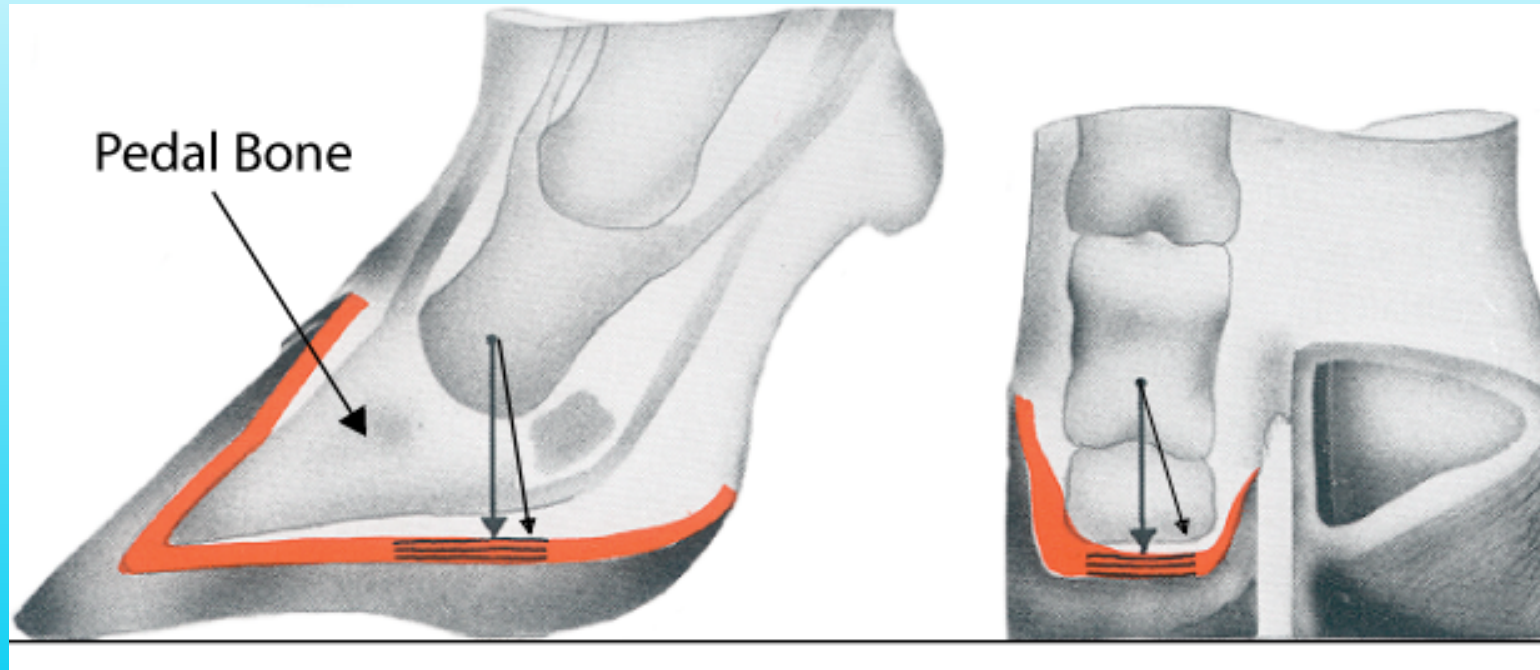


Solar Ulcer



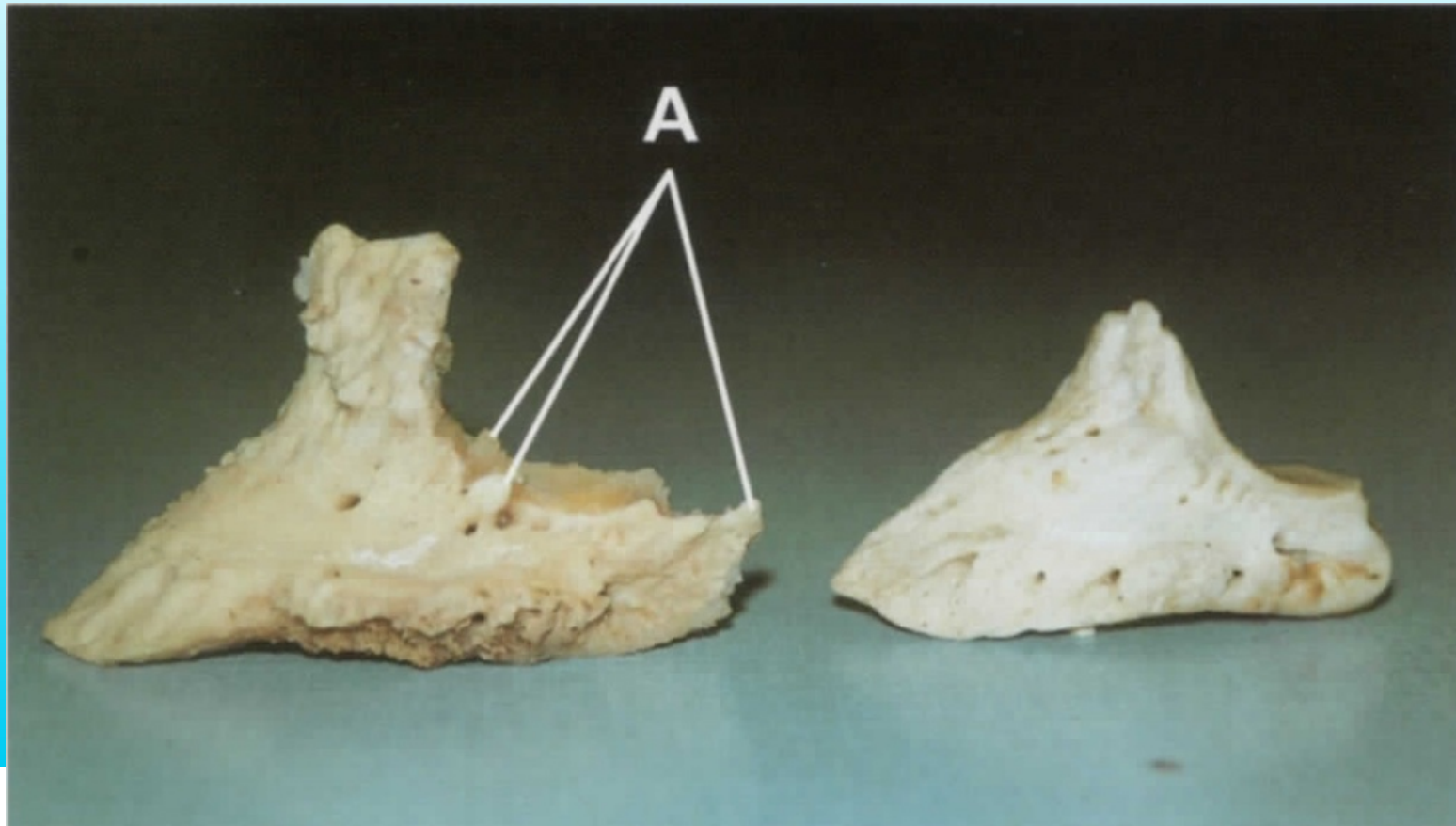


Solar Ulcer



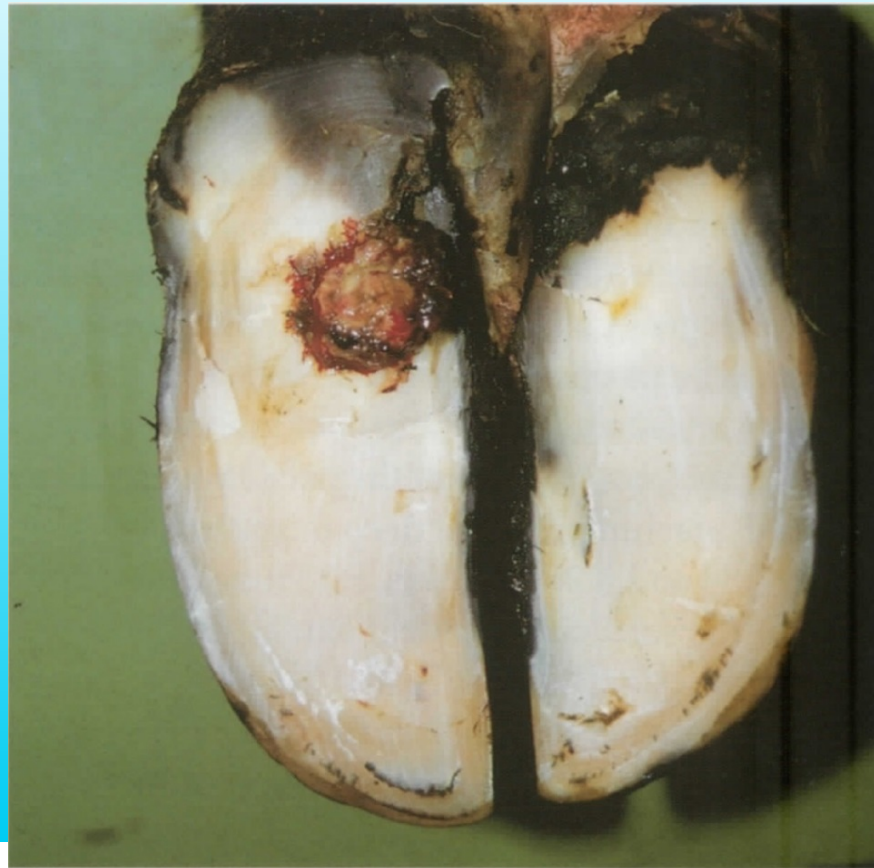

Solar Ulcer





Solar Ulcer



westpoint veterinary group



Solar Ulcer

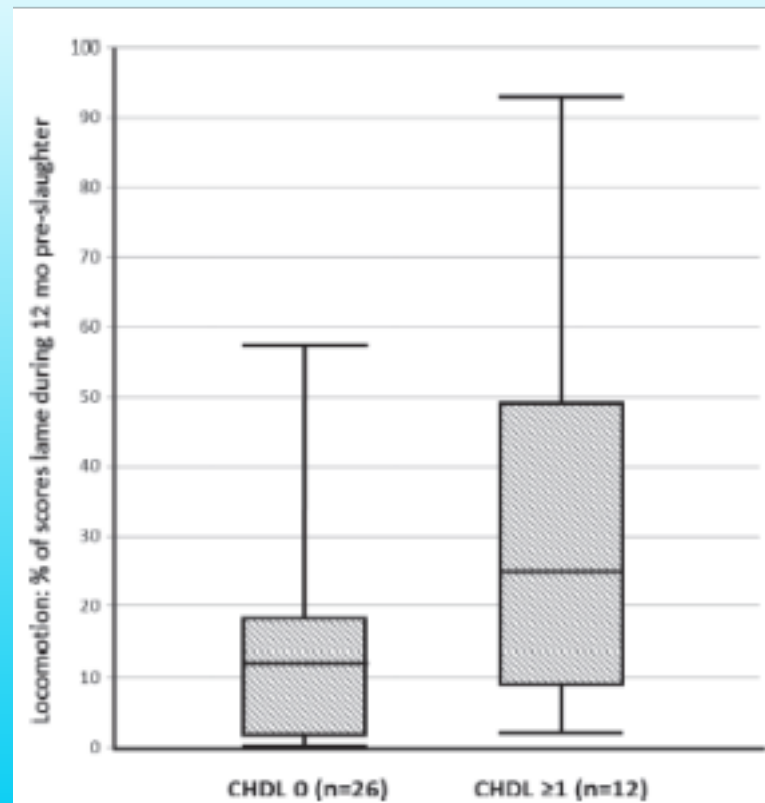


Figure 4. Distribution of the explanatory variable locomotion (the percentage of scores at which a cow was lame during the 12 mo pre-slaughter) within 2 groups of cows that had not (CHDL 0) and that had (CHDL ≥ 1) been recorded as having a claw horn disruption lesion during life. Box plot shows minimum and maximum values, interquartile range (25th and 75th percentiles), and median value.





Digital Dermatitis

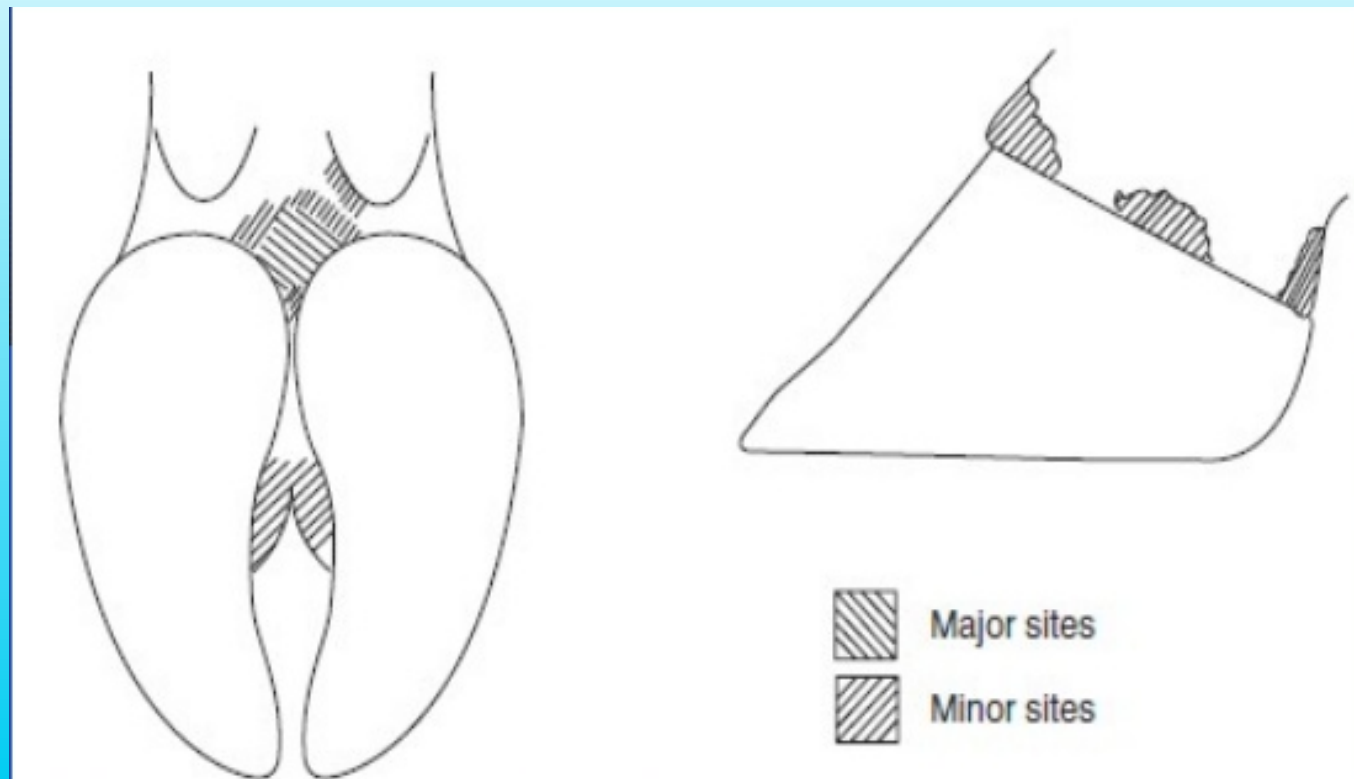


Figure 7.5 Major and minor sites of digital dermatitis.





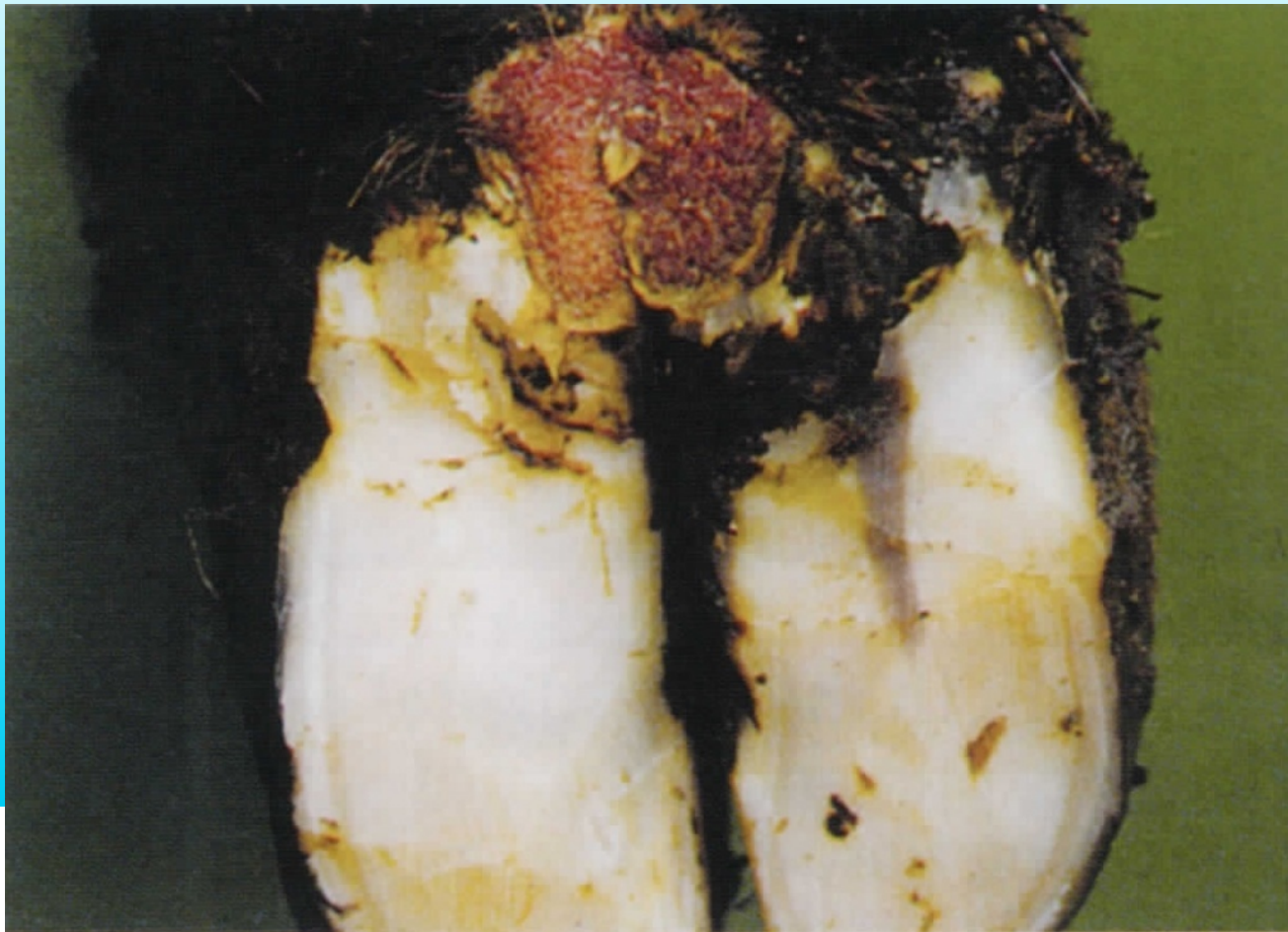Digital Dermatitis

- Disease of hoof skin
- Contagious – caused by a treponeme
- Worldwide distribution – estimated 70% of UK farms affected
- Controllable
 - Infection pressure vs immunity





Digital Dermatitis





Digital Dermatitis

Circumscribed, erosive skin disease

Proliferative

“Hairy Warts”

Dormant

Unhealing lesions



westpoint veterinary group



Hoof Trimming

WHY TRIM HOOVES

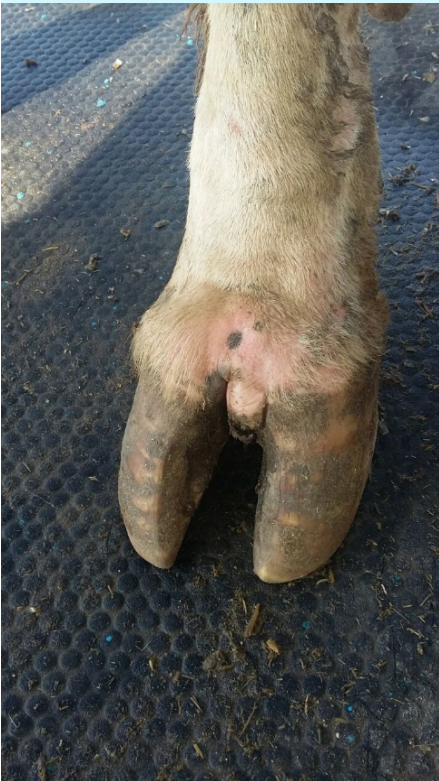- Aim to rebalance hoof
- Remove weight bearing from lesions
- Prevention rather than cure
- As and when needed
- Dry off
- Post calving
- 200-250 DIM
- Whole herd



westpoint veterinary group



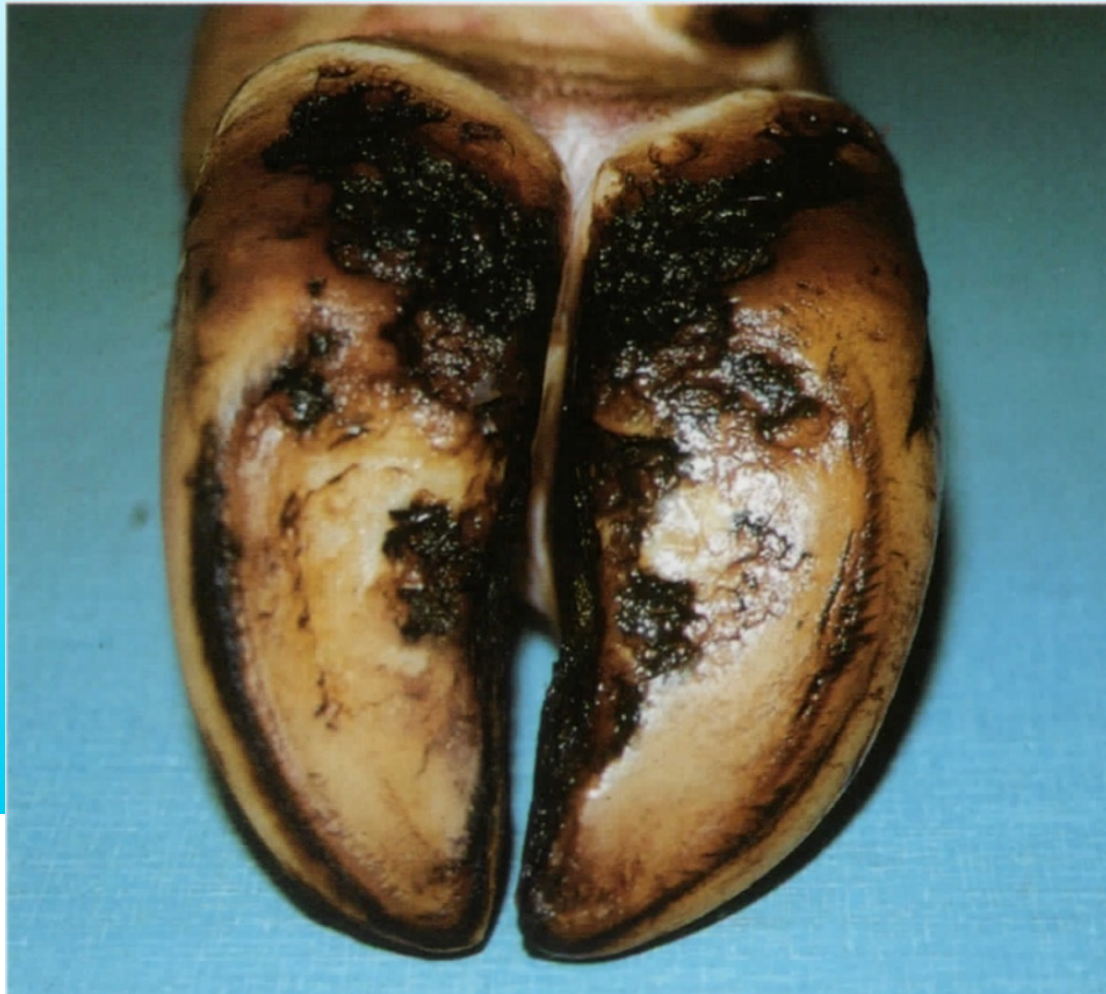Hoof Trimming



westpoint veterinary group



Hoof Trimming



westpoint veterinary group



Hoof Trimming

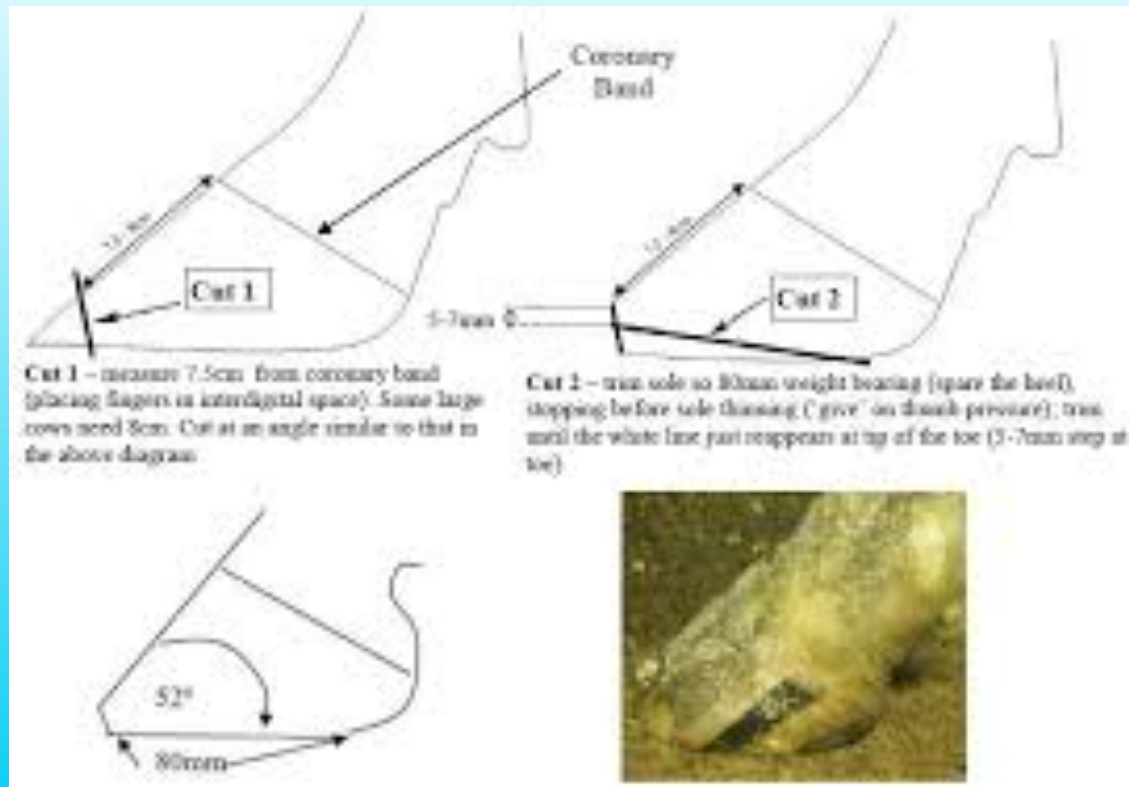
Dutch 5 point foot trimming

- Trim medial claw to correct length and sole depth
- Match lateral claw
- Model axial surface to remove bearing from sole ulcer site
- Remove weight from any lesions in caudal hoof only
- Remove any loose or diseased horn





Hoof Trimming



westpoint veterinary group



Hoof Trimming

- Equipment Required





Hoof Trimming

- Examples of Hoof Trimming



westpoint veterinary group



Footbathing

Essential in control of digital dermatitis:

- Clean hooves
- Kill bacteria
- Harden skin
- Harden claws



westpoint veterinary group



Footbathing

What doesn't work:

- Parlour washings
- Water baths
- Hard work
- Treatment
- Uncomfortable footbaths

What does work:

- Routine
- Cow flow
- Proven chemicals





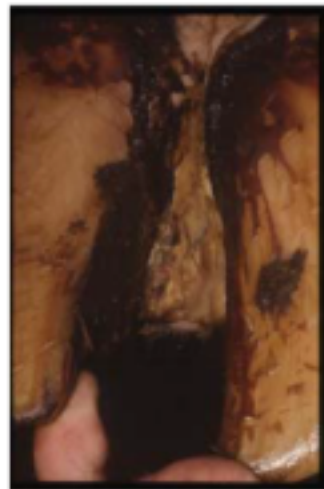
Footbathing



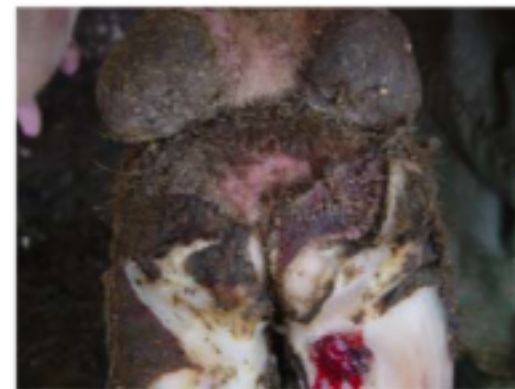Growths
between the
claws



Rotten toes



Cases of
foul



Severe heel erosion,
severe digital dermatitis
and severe sole ulcers
that become deep
infections



Digital Dermatitis Control

- 4 Principles of control
 - Treat active lesions
 - Topical antibiotics very effective
 - Antibiotics shouldn't be used in footbaths
 - Disinfect feet regularly
 - Through a footbath
 - Daily if needed
- Footbath heifers, dry cows and quarantine cows
- Ensure cow cleanliness





Footbath golden rules

- Make it easy
- 1 litre per cow pass (when using disinfectants & Formalin / Copper Sulphate)
- 2 litre per cow pass when using HEALTHY HOOVES
- Keep it clean
- As often as needed
- Minimum 12.5cm depth
- Know your volumes
- Do it! Regular footbathing



westpoint veterinary group



Copper Sulphate

- Proven efficacy for reducing active DD prevalence in a herd
- Does not lead to brittle horns
- Solution vs suspension
- Is not inactivated by organic matter
- Minimum 4% Less than this ineffective
- Minimal hazard to human health
- Only 175 / 200 cow passes to 200 ltr volume



westpoint veterinary group



Healthy Hooves

- Acidifier – Low pH >2 Low pH kills Bacteria
- Contains copper & zinc activated by the low pH
- Less copper build up on land
- Cheaper
- As effective
- 400 / 500 cow passes per 200 ltr volume
- Non hazardous to animal / human skin



westpoint veterinary group



Healthy Hooves

- More cow passes per bath – Copper is ‘topped up’ from suspension as it gets used
- Up to 500 cow passes per 200 litres
- Mix 4 litres of Healthy Hooves with 4 kg Copper Sulphate initially for 200 litres foot bath
- Ongoing use 4 litres of Healthy Hooves
- Low pH aids in killing bacteria



westpoint veterinary group



Footbathing

- Equipment Required



westpoint veterinary group



What Next?

- Learn how to foot trim
- Maximise your benefit from footbathing
- Buy some Healthy Hooves!
- Monitor situation
 - Mobility scoring
 - Lameness case rates
 - Milk yield
 - Fertility performance
 - ££££/\$\$\$\$\$/Lakhs!!



westpoint veterinary group



What Next

- Contact Healthy Hooves for hoof trimming training and footbath equipment and solutions
- Know the condition of your cows
- Mobility Score see hand out
- Healthy Hooves leaflet on Solution
- Healthy Hooves leaflet on Bovi Bath
- **HAPPY HEALTHY COWS GIVE MORE**



westpoint veterinary group